New Zealand Journal of Marine and Freshwater Research

ISSN: 0028-8330 (Print) 1175-8805 (Online) Journal homepage: https://www.tandfonline.com/loi/tnzm20

Use of radiography to determine age class and assist with the post-mortem diagnostics of a Bryde's whale (*Balaenoptera brydei*)

K.A. Stockin , N. Wiseman , A. Hartman , N. Moffat & W. D. Roe

To cite this article: K.A. Stockin , N. Wiseman , A. Hartman , N. Moffat & W. D. Roe (2008) Use of radiography to determine age class and assist with the post-mortem diagnostics of a Bryde's whale (*Balaenoptera brydei*), New Zealand Journal of Marine and Freshwater Research, 42:3, 307-313, DOI: 10.1080/00288330809509958

To link to this article: https://doi.org/10.1080/00288330809509958

Published online: 19 Feb 2010.

New Zealand Journal of Marine and Freshwater Research, 2008, Vol. 42: 307–313
0028–8330/08/4203–0307

Short communication

Use of radiography to determine age class and assist with the post-mortem diagnostics of a Bryde's whale (*Balaenoptera brydei*)

K. A. STOCKIN
Coastal-Marine Research Group
Institute of Natural Resources
Massey University
Private Bag 102904
North Shore MSC
Auckland, New Zealand
email: k.a.stockin@massey.ac.nz

N. WISEMAN
School of Biological Sciences
The University of Auckland
Private Bag 92019
Auckland, New Zealand

A. HARTMAN

N. MOFFAT

W. D. ROE
Institute of Veterinary, Animal and Biomedical Sciences
Massey University
Private Bag 11 222
Palmerston North, New Zealand

Abstract Vessel collisions are considered an important source of mortality for some cetacean species, and this is likely for the New Zealand Bryde's whale (*Balaenoptera brydei*), a species currently classified as "nationally critical". Nevertheless, the occurrence and frequency of vessel strikes involving whales in New Zealand waters is yet to be systematically evaluated. Herein, we document the use of radiography as a diagnostic tool to examine the pectoral flippers of a Bryde's whale carcass recovered from Hauraki Gulf, New Zealand. To determine age class, radiographs were used to assess the degree of epiphysial fusion in the pectoral flippers. Additionally, evidence of bone damage and repair was examined in an attempt to clarify cause of mortality. Radiographs were definitive for age-class determination, revealing the specimen to be a juvenile, as evidenced by open physes, incompletely ossified epiphyses, and incompletely ossified cuboidal bones of the carpus. The degree of epiphyseal development of the distal radial and ulnar secondary ossification centres suggests a late stage two or early stage three degree of development. Radiographs were less definitive in clarifying cause of mortality. Bilateral distal antebrachial fractures were observed on both the left and right pectoral flippers. The fractures evident in the distal right antebrachium of the left flipper were considered atypical of acute blunt trauma. The fracture fragment ends were not sharp edged as expected, but instead exhibited the appearance of remodelled and/or pulverised fracture fragment ends. Regardless of cause, the degree of bone remodelling and callus formation is evidence that the whale likely survived any initial trauma, thus suggesting mortality was not immediate. However, the absence of appropriate histopathology sampling and a systematic necropsy prevent confirmation of this hypothesis.

Keywords growth; mortality; pathology; Hauraki Gulf, New Zealand

INTRODUCTION

Radiographs have been extensively used to diagnose bone and soft tissue disease and to investigate osteology and skeletal development (e.g., Ogden et al. 1981; Cozzi et al. 1985; Ito & Miyazaki 1990; Benke 1993; DiGiancamillo et al. 1998; Guglielmini et al. 2002; Dawson 2003; de Buffrénil et al. 2004; Felts & Spurrell 2005). The evaluation of the degree of fusion of epiphysial plates by means of X-ray examination or the degree of fusion of the hyoid complex has been used extensively to estimate the age of various stranded cetaceans including, but not limited to the striped dolphin *Stenella coerueolalba* (Calzada & Aguilar 1996; Calzada et al. 1997; DiGiancamillo et al. 1998), bottlenose dolphin

M08006; Online publication date 2 September 2008
Received 29 January 2008; accepted 9 June 2008

Tursiops truncatus (Butti et al. 2007), common dolphin *Delphinus delphis* (Cozzi et al. 1985), bottlenose whale *Indopacetus pacificus* (Watson et al. 2008) and Bryde's whale *Balaenoptera edeni* (Perrin et al. 1996).

New Zealand Bryde's whale *B. brydei* (Wiseman 2008) remain a poorly studied species and are currently classified as "nationally critical" (Hitchmough et al. 2007). Despite the occurrence of several confirmed ship strike incidents involving this species (Wiseman 2008), the frequency of vessel collisions involving Bryde's whales in New Zealand waters is yet to be systematically evaluated.

The increase of both maritime traffic and vessel speed is cause for concern since a growing number of cetaceans have become involved in vessel strikes around the world (IWC 2002; Reeves et al. 2003). Collisions involving whales occur with different types of vessels including cargo ships, tankers, cruise liners and fishing vessels (e.g., George et al. 1994). However, most vessel strikes typically involve larger and faster vessels such as cargo ships (Laist et al. 2001; Jensen & Silber 2004). Laist et al. (2001) suggest that collisions generally occur in coastal areas where whales concentrate typically to either feed or breed. Vessel strikes involving Bryde's whales *B. brydei* and *B. edeni* have previously been reported (e.g., Jensen & Silber 2004; Fèlix & Van Waerebeek 2005), although remain uncommon, possibly because of the relatively fast speed and the comparatively smaller body size of Bryde's whales compared with other more frequently affected species (Fèlix & Van Waerebeek 2005).

Herein, we document the use of radiography as a diagnostic tool to investigate age class by interpretation of bone formations. Additionally, evidence of bone damage and repair was used to gain insight into mortality.

MATERIALS AND METHODS

On 3 February 2007, a dead whale was observed floating at 36°37′68S and 174°54′30E, southeast of Tiritiri Matangi Island in Hauraki Gulf, New Zealand. Hauraki Gulf is a relatively shallow (60 m maximum depth), semi-enclosed body of temperate water (Manighetti & Carter 1999) on the east coast of North Island, New Zealand (36°10′S and 36°60′S). Adjacent to the city of Auckland (36°51′S, 174° 46′E), Hauraki Gulf hosts three major shipping channels involving in excess of 4000 commercial vessel movements per year (Ports of Auckland unpubl. data). Owing to weather constraints and logistics associated with carcass retrieval, the dead whale could not be brought ashore until the next day. On 4 February, the carcass was towed to Motutapu Island in Hauraki Gulf, where it was examined and body measurements recorded.

Gross lesions were recorded and photographs taken of any injuries or abnormalities observed. Blubber was flensed laterally along the thorax to expose tissues underneath areas of apparent bruising. Field logistics and the decompositional state of the carcass prevented a systematic necropsy. However, in an attempt to assess age class and better understand the extent of apparent fractures within the pectoral flippers, both left and right flippers were surgically removed from the carcass using flensing knives. Each pectoral flipper was carefully extracted *in situ* by amputation at the level of the scapulohumeral (shoulder) joint by incising all soft tissue attachments between the scapula and the humerus. The pectoral flippers were then carefully packed flat and transported to Massey University, where they were stored frozen at –20°C until X-rayed.

Radiographical techniques

Each pectoral flipper was thawed and cleaned before being X-rayed. A total of six 35 × 43 cm films were taken of each flipper in the dorsoventral projection using a Phillips Optimus Diagnost Ceiling System (40–150 kV; 2–850 mAs; triple focal point 0.1–2.0 mm; rotating anode 3400 revolutions/min). The radiographs illustrated both pectoral flippers in their entirety from the humerus to the metacarpal/phalanges. X-rays were taken at a film-to-source distance of 110 cm at exposures 70–90 kV, 5–50 mAs. A fast screen type was used in bucky with an oscillating grid. The exposure factors used varied with thickness of the flipper. Films were processed in an automatic processor and examined by the unaided eye on a standard radiographic illuminator. Assessment of the bone lesions was based upon commonalities of disease amongst species.

The development of the epiphyses and their fusion to the diaphyses on the different bones was graded according to Ogden et al. (1981), whose rating scheme is as follows: stage 0, no secondary ossification centre present; stage 1, the secondary ossification centre is present but occupies less than 50% of the width of the adjacent bone; stage 2, the secondary ossification centre occupies 50–100% of the adjacent bone; stage 3, the distance between the epiphysis and metaphysis of bone begins to diminish; stage 4, physis (epiphyseal or growth plate) begins to close;



Fig. 1 Ventral surface of the Bryde's whale (*Balaenoptera brydei*) showing bruising around genital region and peri- or post-mortem soft tissue damage. (Photo: Ciaran Edwards.)

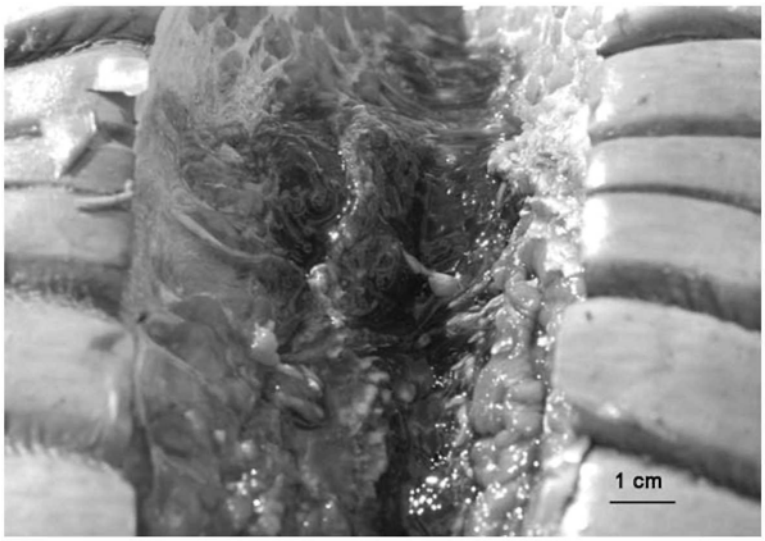

Fig. 2 Subcutaneous haemorrhage and oedema (bruising) evident under the throat pleats of the Bryde's whale (*Balaenoptera brydei*).

stage 5, physis is completely closed and radiodense physeal line traverses the width of the bone; stage 6, remodelling of the physeal region, consisting of the replacement of the physeal line by mature bone tissue. As a consequence, less than 50% to no evidence of the physeal remains at this stage.

RESULTS

The carcass was classified as a Bryde's whale, based on the three longitudinal rostral ridges and extended throat grooves (Reeves et al. 2002). Examination of the genital slits confirmed the animal to be a male measuring 11.5 m in total body length. Gross pathology revealed several regions of the carcass had been scavenged post-mortem including areas around the genitals slits. Skin loss and several areas of tissue damage along the ventral surface were also apparent (Fig. 1). The carcass was estimated to be at stage 3 of decomposition based on levels of observed autolysis (Duignan & Jones 2005). Body condition and axillary girth (circumference immediately behind the flippers) could not be accurately assessed owing to post-mortem bloating. However, no obvious signs of emaciation were apparent and blubber thicknesses measured under the dorsal fin and along the left flank were 4 cm and 5 cm, respectively. Sections of flensed blubber along the left flank revealed extensive subcutaneous haemorrhaging and oedema (Fig. 2).

The pectoral flippers measured 0.3 m wide and had a 1.15 and 1.50 m internal and external length, respectively. On the leading edge of the left flipper, there was a full thickness V-shaped skin laceration

Fig. 3 V-shaped skin laceration on the leading edge of the left pectoral flipper of the Bryde's whale (*Balaenoptera brydei*) showing sharp wound margins.

with loss of intervening skin underlying bone. The wound had sharp margins, with apparent bruising of the surrounding soft tissues (Fig. 3).

Radiographs revealed open physes, incompletely ossified epiphyses, and incompletely ossified cuboidal bones of the carpus (Fig. 4). The degree of epiphyseal development of the distal radial and ulnar secondary ossifications centres placed this specimen in the late stage 2 or early stage 3 degree of development (Ogden et al. 1981). No congenital abnormalities were observed.

Bilateral distal antebrachial fractures were observed on the left and right pectoral flippers. In the distal diaphysis of both antebrachii there were comminuted fractures of the distal radius and ulna. Within the left pectoral flipper there was a large bone fragment missing from the medial aspect of the radius extending both proximal and distal to the fracture site (Fig. 5). This injury would have been compatible with a large butterfly fragment that presumably escaped from the skin laceration. The fracture sites exhibited rounded edges and bone remodelling compatible with attempted healing. The fractures in the distal right antebrachium exhibited a more pulverised appearance. There was one large piece of bone central in the distal right radial fracture that appeared less remodelled than the surrounding bone fragments that may have been forming a sequestrum. A sequestrum is a devascularised piece of bone that cannot be remodelled and often can become infected owing to the lack of blood supply. The bone fragments of the distal right antebrachial fractures showed ill-defined margins with bone proliferation from bone remodelling.

DISCUSSION

We examined patterns of epiphysial fusion in the flipper to determine relative age class. Results suggest that the Bryde's whale was immature, as evidenced by open physes, incompletely ossified epiphyses and incompletely ossified cuboidal bones of the carpus (Ogden et al. 1981). The degree of epiphyseal development of the distal radial and ulnar secondary ossifications centres placed this specimen in the late stage 2 or early stage 3 degree of development, based upon the classification system developed by Ogden et al. (1981). Correlation of this classification system to age in other cetacean species suggests stage 4 of ossification corresponds to reproductive maturation, e.g., Dall's porpoise *Phocoenoides dalli* (Ogden et al. 1981) and bottlenose whale (Watson et al. 2008). This designation of immaturity concurs with body length, which for this specimen fell just within the expected range for a juvenile *B. brydei* (Rice 1998).

Results presented also provide evidence that the carcass recovered from Hauraki Gulf had suffered severe trauma, possibly resulting from a ship collision. Other potential causes of mortality (e.g., drowning as a result of net entanglement) were deemed less likely owing to a lack of indicative external lacerations. Furthermore, bilateral distal antebrachial fractures evident suggest mortality was not instant but rather a consequence of injuries sustained. The fractures in the distal right antebrachium exhibited a pulverised appearance that is considered atypical of acute blunt trauma (A. Hartman pers. obs.). The degree of bone remodelling and callus formation evident suggests

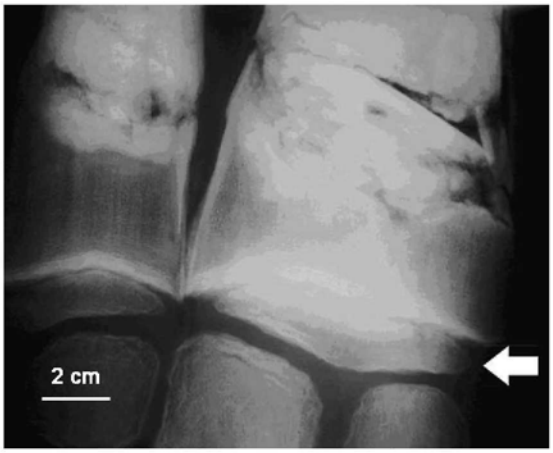

Fig. 4 Radiograph of right pectoral flipper of the Bryde's whale (*Balaenoptera brydei*) showing open physes and incompletely ossified epiphyses (white arrow) and cuboidal bones of the carpus. The open physis (growth plate) is just above the epiphysis. (Note the piece of bone that has more sharply defined margins in the radial fracture gap (larger bone) which is similar for a sequestrum (devascularised piece of bone).)

Fig. 5 Radiograph of left pectoral flipper of the Bryde's whale (*Balaenoptera brydei*) showing a large bone fragment missing from the medial aspect of the radius extending both proximal and distal to the fracture site. (Note the mildly rounded fracture margins in the lateral aspect of the radial fracture site and associated with the ulnar fracture.)

the whale survived for at least a period of 10 to 14 days post-trauma since attempted bone healing was evident (A. Hartman pers. obs.). Potentially, the rounding of the fracture fragment ends may represent attempted swimming after traumatic fracture, thus resulting in motion at the fracture site and rounding of the margins.

Injuries sustained as a result of the initial trauma may potentially have prevented this animal foraging and/or diving. Hauraki Gulf is an important feeding area for this species (Baker & Madon 2007), which could explain the concentrated occurrence of Bryde's whales in these coastal waters (Wiseman 2008). The absence of a systematic necropsy prevented examination of the digestive tract and any subsequent stomach content analysis. Furthermore, it is possible that post-mortem bloating may have potentially obscured evidence of emaciation. Olsen (1913) recorded blubber thickness in Bryde's whales that ranged from 3.5 cm for diseased individuals to 7 cm in pregnant females. Clarke & Aguayo (1965) recorded a blubber thickness of 6 cm for a Bryde's whale examined off Chile. Blubber thickness in the New Zealand specimen was intermediate and thus provides little indication as to whether or not foraging was impeded. Another plausible yet indirect consequence of the induced trauma includes possible infection associated with sustained injuries. The apparent presence of a sequestrum may support this theory although the lack of appropriate post-mortem procedures, particularly histopathology, prevents further investigation of this hypothesis.

The New Zealand Bryde's whale is a nationally threatened species (Hitchmough et al. 2007) that is largely restricted to the Hauraki Gulf region (Baker & Madon 2007). Its distribution makes it locally vulnerable to a range of anthropogenic impacts including vessel strike (Wiseman 2008), tourism (Suisted & Neale 2004), and entanglement in fishing gear (Lloyd 2003). The region hosts three major shipping channels and several recreational vessel types including large motor yachts, fast inter-island ferries, dolphin tour boats, and jet skis (Stockin et al. 2008). Recently, the New Zealand Department of Conservation stated that management of this threatened species would focus on seeking to reduce Bryde's whale mortalities in Hauraki Gulf (Suisted & Neale 2004). However, to date little concerted effort has been made to either quantify or mitigate ship strike incidents involving Bryde's whales in this region.

Our research findings highlight the need for detailed post-mortem examinations to be conducted on all whale carcasses suspected of ship strike.

Although radiography and post-mortem observations offer insight, particularly into age class, they are not substitutes for systematic sampling. Instead, multiple methodologies including necropsy, histopathology, and radiology should be used collectively to investigate each mortality incident.

ACKNOWLEDGMENTS

The authors thank the New Zealand Department of Conservation, particularly Karl McLeod, Ciaran Edwards and Bill Trusewich who facilitated many aspects of this research. We also acknowledge Rochelle Constantine (The University of Auckland) for onsite assistance with measurements and Mike Corbett for his logistical assistance. Thanks are extended to the radiology department, Institute of Veterinary, Animal and Biomedical Sciences at Massey University, especially Linda Darragh and Sonia Torwick. Finally, we thank Mauro DiGiancamillo and Weihong Ji for providing comments which improved earlier versions of this manuscript.

REFERENCES

Baker AN, Madon B 2007. Bryde's whales (*Balaenoptera* cf. *brydei* Olsen 1913) in the Hauraki Gulf and north-eastern New Zealand waters. Science for Conservation 272. Department of Conservation, Wellington, New Zealand. 23 p.

Benke H 1993. Investigations in the osteology and the functional morphology of the flipper of whales and dolphins (*Cetacea*). Investigations on Cetacea 24: 9–52.

Butti C, Corain L, Cozzi B, Podestà M, Pirone A, Affronte M, Zotti A 2007. Age estimation in the Mediterranean bottlenose dolphin *Tursiops truncatus* (Montagu 1821) by bone density of thoracic limb. Journal of Anatomy 211: 639–646.

Calzada N, Aguilar A 1996. Flipper development in the Mediterranean striped dolphin (*Stenella coeruleoalba*). The Anatomical Record 245: 708–714.

Calzada N, Aguilar A, Grau E, Lockyer C 1997. Patterns of growth and physical maturity in the western Mediterranean striped dolphin, *Stenella coeruleoalba* (Cetacea: Odontoceti). Canadian Journal of Zoology 75: 632–637.

Clarke R, Aguayo AL 1965. Bryde's whale in the Southeast Pacific. Norsk Hvalfangst-Tidende 7: 141–148.

Cozzi B, DeFrancesco I, Cagnolaro L, Leonardi L 1985. Radiological observations on the skeletal development in fetal and newborn specimens of *Delphinus delphis* L. and *Stenella coeruleoalba* (Meyen). Atti della Società Italiana di Scienze Naturali e del Museo Civico di Storia Naturale di Milano 126: 120–136.

Dawson SD 2003. Patterns of ossification in the manus of the harbor porpoise (*Phocoena phocoena*): hyperphalangy and delta-shaped bones. Journal of Morphology 258: 200–206.

de Buffrénil V, Dabin W, Zylberberg L 2004. Histology and growth of the cetacean petro-tympanic bone complex. Journal of the Zoological Society of London 262: 371–381.

DiGiancamillo M, Rattegni G, Podestà M, Cagnolaro L, Cozzi B, Leonardi L 1998. Postnatal ossification of the thoracic limb in striped dolphins (*Stenella coeruleoalba*) (Meyen, 1833) from the Mediterranean Sea. Canadian Journal of Zoology 76: 1286–1293.

Duignan PJ, Jones GW 2005. Autopsy of cetaceans including those incidentally caught in commercial fisheries, 2002/03. DOC Science Internal Series 195. Department of Conservation, Wellington, New Zealand. 22 p.

Fèlix F, Van Waerebeek K 2005. Whale mortality from ship strikes in Ecuador and West Africa. Latin American Journal of Aquatic Mammals 4: 55–60.

Felts WJL, Spurrell FA 2005. Structural orientation and density in cetacean humeri. American Journal of Anatomy 116: 171–203.

George JC, Philo LM, Hazard K, Withrow D, Carroll GM, Suydam R 1994. Frequency of killer whale (*Orcinus orca*) attacks and ship collisions based on scarring on bowhead whales (*Balaena mysticetus*) of the Bering-Chukchi-Beaufort Seas stock. Arctic 47: 247–255.

Guglielmini C, Zotti A, Bernardini D, Pietra M, Podesta M, Cozzi B 2002. Bone density of the arm and forearm as an age indicator in specimens of stranded striped dolphins (*Stenella coeruleoalba*). The Anatomical Record 267: 225–230.

Hitchmough RA, Bull L, Cromarty P 2007. New Zealand Threat Classification System lists—2005. Department of Conservation, Wellington, New Zealand. 194 p.

Ito H, Miyazaki N 1990. Skeletal development of the striped dolphin (*Stenella coeruleoalba*) in Japanese waters. Journal of the Mammalogy Society of Japan 14: 79–96.

IWC 2002. Report of the Scientific Committee Annex M. Estimation of bycatch and other human-induced mortality. International Whaling Commission 54(4): 19–24.

Jensen AS, Silber GK 2004. Large whale ship strike database. US Department of Commerce, NOAA Technical Memorandum NMFS-OPR-25. 37 p.

Laist DW, Knowlton AR, Mead JG, Collet AS, Podesta M 2001. Collisions between ships and whales. Marine Mammal Science 17: 35–75.

Lloyd BD 2003. Potential effects of mussel farming on New Zealand's marine mammals and seabirds: a discussion paper. Department of Conservation, Wellington, New Zealand. 34 p.

Manighetti B, Carter L 1999. Across-shelf sediment dispersal, Hauraki Gulf, New Zealand. Marine Geology 160: 271–300.

Ogden JA, Conlogue GJ, Rhodin AG 1981. Roentgenographic indicators of skeletal maturity in marine mammals (Cetacea). Skeletal Radiology 7: 119–123.

Olsen O 1913. On the external characteristics and biology of Bryde's whale (*Balaenoptera brydei*) a new rorqual from the coast of South Africa. Proceedings of the Zoological Society of London: 1073–1090.

Perrin WF, Dolar LL, Orega E 1996. Osteological comparison of Bryde's whales from the Philippines with specimens from other regions. Report of the International Whaling Commission 46: 409–413.

Reeves RR, Stewart BS, Clapham PJ, Powell JA 2002. Guide to marine mammals of the world. New York, Chanticleer Press Inc. 527 p.

Reeves RR, Smith BD, Crespo E, Notarbartolo di Sciara G (compilers) 2003. Dolphins, whales and porpoises: 2002–2010 Conservation action plan for the world's cetaceans. IUCN/SSC Cetacean Specialist Group. IUCN, Gland, Switzerland and Cambridge, United Kingdom. 139 p.

Rice DW 1998. Marine mammals of the world: systematics and distribution. Society for Marine Mammalogy, Special Publication No. 4. Lawrence, Kansas, United States. 231 p.

Stockin KA, Lusseau D, Binedell V, Wiseman N, Orams MB 2008. Tourism affects the behavioural budget of the common dolphin (*Delphinus* sp.) in the Hauraki Gulf, New Zealand. Marine Ecology Progress Series 355: 287–295.

Suisted R, Neale D 2004. Department of Conservation marine mammal action plan for 2005–2010. Department of Conservation, Wellington, New Zealand. 89 p.

Watson A, Kuo TF, Yang WC, Yao CJ, Chou LS 2008. Distinctive osteology of distal flipper bones of tropical bottlenose whales, *Indopacetus pacificus*, from Taiwan: Mother and calf, calf with polydactyly. Marine Mammal Science 24: 398–410.

Wiseman N 2008. Genetic identity and ecology of Bryde's whales in the Hauraki Gulf, New Zealand. Unpublished PhD thesis, University of Auckland, Auckland, New Zealand. 259 p.